

We introduce a case of 59-year-old female with a nonspecific abdominal pain and palpable mass in the central abdomen on the left side. A well circumscribed, large tumour of the left kidney compressing abdominal structures such as aorta, main inferior vein and descending large bowel was visualised by radiological studies. There was no haematuria, and both kidneys were found to be secreting urine. Total left transperitoneal nephrectomy was performed. Microscopic examination revealed tightly packed, uniform, small epithelial tumour cells forming small acini and tubules. There was no infiltrative growth pattern. Vascular invasion, pleomorphism or anaplasia and mitotic activity were absent. After a microscopic and immunohistochemical examination, metanephric adenoma (MA) was diagnosed. Metanephric adenoma is a rare benign renal tumour. Only 0.2% of adult renal epithelial neoplasms are diagnosed as MAs. The case description is accompanied by a literature review in which we characterise this entity (its aetiology, symptoms, macro- and microscopic features). Differential diagnosis and therapeutic approach are also discussed.

Key words: metanephric adenoma, nephrogenic nephroma.

Contemp Oncol (Pozn) 2014; 18 special issue
DOI: 10.5114/wo.2014.40608

Metanephric adenoma of the left kidney in a 59-year-old female

Jacenty Szukalski^{1,2,3}, Izabela Neska-Długosz^{1,2}, Szymon Kwiatkowski⁴, Jacek Czeźnin⁴, Alina Patalas⁴, Andrzej Marszałek^{1,2,5}

¹Chair of Clinical Pathology, *Collegium Medicum* in Bydgoszcz, Nicolaus Copernicus University, Toruń, Poland

²Department of Clinical Pathomorphology, University Hospital No. 1, Bydgoszcz, Poland

³Division of Pathology, Dr Błażek's District Hospital, Inowrocław, Poland

⁴Department of Urology and Urologic Oncology, Dr Błażek's District Hospital, Inowrocław, Poland

⁵Department of Pathology, Poznan University of Medical Sciences, Poznan, Poland

Introduction

Metanephric adenoma (MA) – also called embryonal adenoma, nephrogenic nephroma or renal epithelial tumour – is a rare benign renal tumour [1, 2]. Only 0.2% of adult renal epithelial neoplasms are diagnosed as MAs [3]. Since 1979 about 130 cases of this adenoma have been reported [4]. The tumour occurs usually in the 6th and 7th decade of life, and it is seen predominantly in females – 2 : 1 F : M ratio [5]. Metanephric adenoma very rarely occurs in children (the youngest described patient was only 15 months old) [4, 6]. About 50% of tumours are incidental findings. The remaining 50% present such symptoms as abdominal or flank pain, haematuria, palpable mass, hypertension and paraneoplastic symptoms – polycythemia and hypercalcemia [1, 7, 8].

Case report

A 59-year-old female suffering from nonspecific abdominal pain was admitted to a primary health care physician. Physical examination revealed palpable mass on the left central abdomen, and therefore primary ultrasound (US) study was performed. US examination included the following findings: “An evident heterogenous change – 13 cm × 18 cm in dimension – present in the place of palpable mass in the central abdomen on the left side. The change was with visible, probably kidney-derived, blood flow”. Clinical diagnosis was tumour of the left kidney with concomitant abdominal pain without hematuria. Computer tomography (CT) of the abdomen revealed: “Tumour of the lower pole of the left kidney, 8 cm × 10 cm × 18 cm in dimension, saturating heterogeneously on enhanced CT (attenuated areas could be infarct areas). The tumour shifts abdominal organs, i. e. aorta and main inferior vein. The descending large bowel was heavily bruised between the tumour and abdominal wall. No extrarenal tissue infiltration was found. No enlargement of abdominal and pelvic lymph nodes and venal thrombi was found. Both kidneys were found to be secreting urine”. The patient was admitted to the Department of Urology and Urologic Oncology. A second US study revealed: “The hole left kidney remodelled by solid change, probably neoplastic in nature. The tumour dimensions are 181 mm × 84 mm × 121 mm. The tumour adheres to abdominal aorta and vertebra, and constricts the iliolumbar muscle” (Fig. 1). Total transperitoneal left nephrectomy was performed.

The excised kidney with the tumour was fixed in 10% buffered formalin and sent to the Department of Pathology. Macroscopically, the tumour was found to be well circumscribed, solid, firm, light tan, 15 cm in diameter and compressing the kidney's parenchyma (Fig. 2). Representative samples were

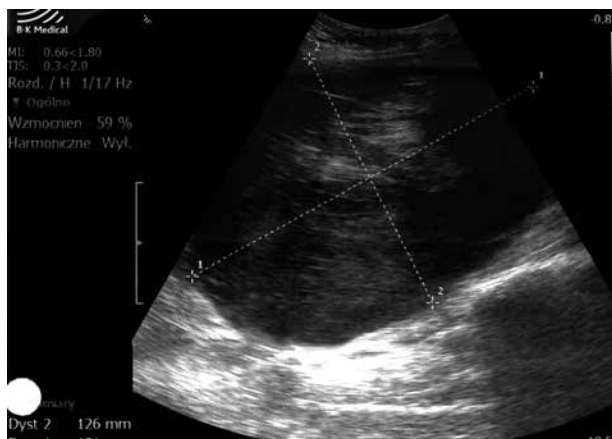


Fig. 1. Abdominal US study: Left kidney remodelled by solid hypoechoic tumour 181 mm × 84 mm × 121 mm in dimension

taken and paraffin-embedded. After routine processing, 4- μ m-thick sections were stained with haematoxylin-eosin and viewed under a light microscope.

Microscopically, the tumour was well separated from the kidney's parenchyma. There were tightly packed, uniform, small epithelial cells forming small acini and tubules. The cells had a scanty, clear cytoplasm. Nuclei were slightly bigger than lymphocytes, irregularly rounded/ovoid with delicate chromatin (Fig. 3). There was no infiltrative growth pattern, vascular invasion, pleomorphism or anaplasia, and mitotic activity was absent.

A representative section was stained immunohistochemically with high quality antibodies against cytokeratin 7 (CK7) (DAKO), vimentin (DAKO), and Ki 67 (DAKO). The immunohistochemistry stains were viewed under a light microscope. There was no expression of CK7 or vimentin in tumour cells. Ki67 index was approximately 1%.

According to microscopic and immunohistochemical manifestation of the entity, metanephric adenoma was diagnosed.

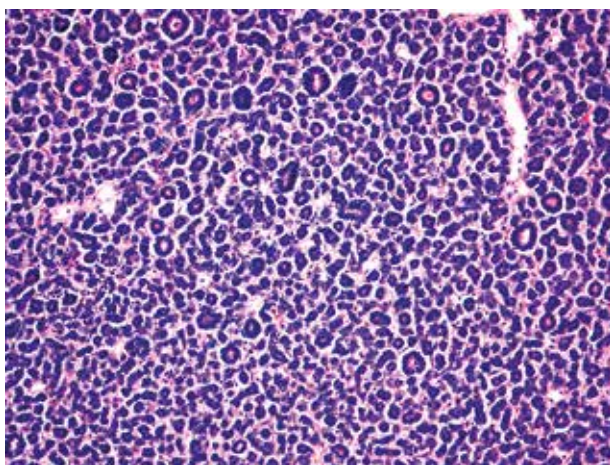


Fig. 3. Microscopic slide, HE, magnification 10 \times . Tightly packed, uniform, small epithelial cells forming small acini and tubules. Tumour cells with scanty, clear cytoplasm and irregularly rounded/ovoid nuclei with delicate chromatin. Vascular invasion, pleomorphism, anaplasia and mitotic activity are absent

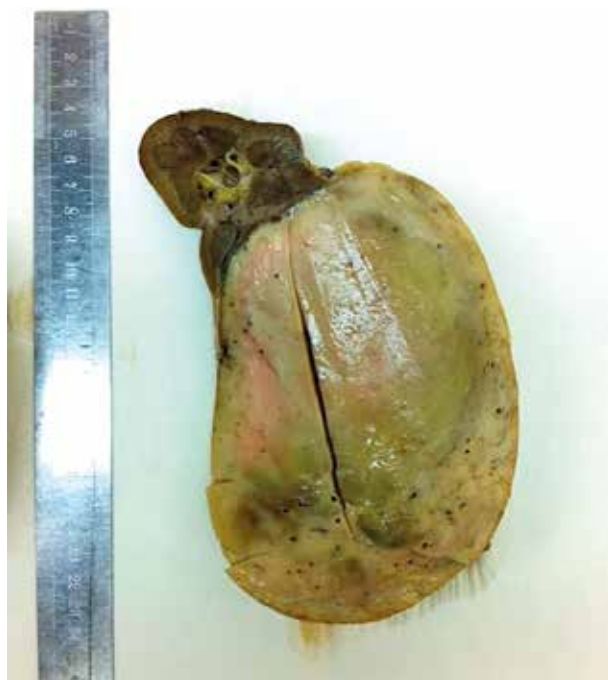

Fig. 2. Macroscopically: Well circumscribed, solid, firm, light tan tumour 15 cm in diameter compressing the kidney's parenchyma

Discussion

Like oncocytoma and papillary adenoma, MA is a benign renal epithelial tumour. The same as (occurring mainly in children) Wilms' tumour (WT), MA develops from postnatal remnants of the metanephric blastema [6]. Therefore, MA have been considered by some authors to be a benign counterpart of WT in adults.

Radiological studies of a few MA cases have brought variable results. On US (ultrasound scan) the tumour can be iso-, hypo- or hyperechoic (compared to the adjacent renal tissue). The tumour is considered to be rather hypovascular, so colour Doppler US usually shows no vascular flow. On unenhanced CT the tumour has higher saturation than the adjacent kidney, but on enhanced CT it is usually of lower attenuation. Both T1- and T2-weighted MRI show a lower signal intensity in the tumour than in adjacent renal parenchyma [1, 4].

Some authors suggest a preoperative diagnostic biopsy of the tumour, but cytology diagnosis using fine needle aspiration can be extremely difficult and immunohistochemical analysis on cell block sections could be required [1, 4].

Macroscopically, most MAs are well circumscribed (but not encapsulated), round, solid, firm and have a light tan/white surface [1, 3]. Occasionally, some tumours can be cystic. Larger tumours may be hemorrhagic and softer [1, 5, 7]. Multifocality is uncommon. Most adenomas are 30–60 mm in diameter, but the range of size is wide. The largest recorded tumour measured 20 cm × 19 cm × 15 cm [7, 8].

Microscopically MA is a highly cellular tumour, composed of small uniform epithelial cells arranged in very small acini and tubules separated by acellular, oedematous or hyalinised stroma. Cells have a scanty, clear or pink

Table 1. Immunohistochemical markers helpful in differential diagnosis of metanephric adenoma

	CK7	WT1	CD57	AMACR
MA	neg./focally posit.	posit./neg.	diffuse posit.	neg./posit.
PRCC	diffuse posit.	neg.	neg.	posit.
WT	neg.	posit.	neg.	neg.

MA – metanephric adenoma; PRCC – papillary renal cell carcinoma; WT – Wilms' tumour; CK7 – cytokeratin 7; WT1 – Wilms' tumour antigen 1; CD57 – cluster of differentiation antigen 57; AMACR – Alpha-methylacyl-CoA racemase protein

cytoplasm. Nuclei are slightly bigger than lymphocytes, irregularly rounded/ovoid with delicate chromatin. Glomeruloid bodies composed of lobulated papillary projections are common [4, 8]. No, or just a few, blood vessels can be seen. About 20% of tumours have psammoma bodies/dystrophic calcifications within hyalinised stroma [4, 5]. Metanephric adenoma never presents an infiltrative growth pattern, vascular invasion, pleomorphism or anaplasia and has virtually no or extremely low mitotic activity [2].

These features are helpful in differential diagnosis between MA and epithelial variant of Wilms' tumour, without anaplasia. Our adenoma shares microscopic features not only with WT, but also with the solid variant of papillary renal cell carcinoma type I (PRCC). Some fluorescence *in situ* hybridisation (FISH) and classic genetic studies suggested a genetic relationship between MA and PRCC through sharing trisomies of the 7th and 17th chromosome and loss of a Y chromosome in these entities. Other studies have found normal, or variants of normal karyotypes in MA. Nowadays, most investigators assume that these tumours are not genetically related [3, 9, 10]. Consequently, the relationship between MA, WT and PRCC is a still a matter of controversy. Appropriate differentiation of MA from these two entities is crucial because an adjuvant therapy is considered after surgical resection of WT and PRCC. Less commonly, the differential diagnosis of our adenoma includes metastatic lung carcinoma, metastatic papillary thyroid carcinoma and metastatic poorly differentiated (insular) thyroid carcinoma [2, 5].

The immunohistochemical panel shown in Table 1 can be useful in the differentiation of PRCC and WT from MA (Table 1). Metanephric adenoma may also show positivity for vimentin, S-100 protein, EMA, lysozyme and α -1-antitrypsin [1].

Most reports describe total nephrectomy as a golden standard treatment for MA. Many authors believe that partial nephrectomy should be seen as an option because it is a procedure with better renal function preservation. Furthermore, in 2004 a laparoscopic total nephrectomy was performed for MA treatment in 31-year-old female, and in 2007 a laparoscopic partial nephrectomy was made for MA treatment in a 47-year-old male [1].

In conclusion, although MA is a rare kidney tumour, the possibility of its occurrence should not be forgotten. The radiological findings are variable, but the tumour is usually solid, well-circumscribed and hypovascular. Metanephric adenoma is usually asymptomatic or causes abdominal pain and concerns middle-aged women. Combining these

features could prompt a partial nephrectomy instead of total nephrectomy.

The authors declare no conflict of interest.

References

- Torricelli FC, Marchini GS, Campos RS, Gil AO. Metanephric adenoma: clinical, imaging and histological findings. *Clinics* 2011; 66: 359-61.
- Pins MR, Jones EC, Martul EV, Kamat BR, Umlas J, Renshaw AA. Metanephric adenoma-like tumours of the kidney. *Arch Pathol Lab Med* 1999; 123: 415-20.
- Burger M, Junker K, Denzinger S, Schubert T, Stoehr R, Wieland WF, Hartmann A. Metanephric adenoma of the kidney: a clinicopathological and molecular study of two cases. *J Clin Pathol* 2007; 60: 832-4.
- Bastide C, Rambeaud JJ, Bach AM, Russo P. Metanephric adenoma of the kidney: clinical and radiological study of nine cases. *BJU Int* 2009; 103: 1544-8.
- Obulareddy SJ, Xin J, Truskinovsky AM, Anderson JK, Franklin MJ, Dudek AZ. Metanephric adenoma of the kidney: an unusual diagnostic challenge. *Rare Tumors* 2010; 2: 103-5.
- Loeser A, Katzenberger T, Spahn M, Gerharz EW, Riedmiller H. Metanephric adenoma in a two-year-old child. *Urol Int* 2009; 83: 119-21.
- Patankar T, Puneekar S, Madiwale C, Prasad S, Hanchate V. Metanephric adenoma in a solitary kidney. *The Brit J Radiol* 1999; 72: 80-1.
- Eble JN, Grignon DJ, Moch H. Metanephric adenoma and metanephric adenofibroma. In: *The WHO Classification of the Urinary System and Male Genital Organs*. Eble JN, Sauter G, Epstein JI, Sesterhenn IA (eds.). 1st ed. IARC Press, Lyon 2004; Chapter 1; pp. 44-6.
- Brunelli M, Eble JN, Zhang S, Martignoni G, Cheng L. Metanephric adenoma lacks the gains of chromosomes 7 and 17 and loss of Y that are typical of papillary renal cell carcinoma and papillary adenoma. *Mod Pathol* 2003; 16: 1060-3.
- Olgac S, Hutchinson B, Tickoo SK, Reuter VE. Alpha-methylacyl-CoA racemase as a marker in the differential diagnosis of metanephric adenoma. *Mod Pathol* 2006; 19: 218-24.

Address for correspondence

Izabela Neska-Długosz, MD
Chair and Department of Clinical Pathology
University Hospital No. 1 in Bydgoszcz
Collegium Medicum in Bydgoszcz,
UMK in Torun Curie-Skłodowskiej 9
85-094 Bydgoszcz
e-mail: iznes@poczta.onet.pl

Submitted: 23.03.2012

Accepted: 28.05.2012